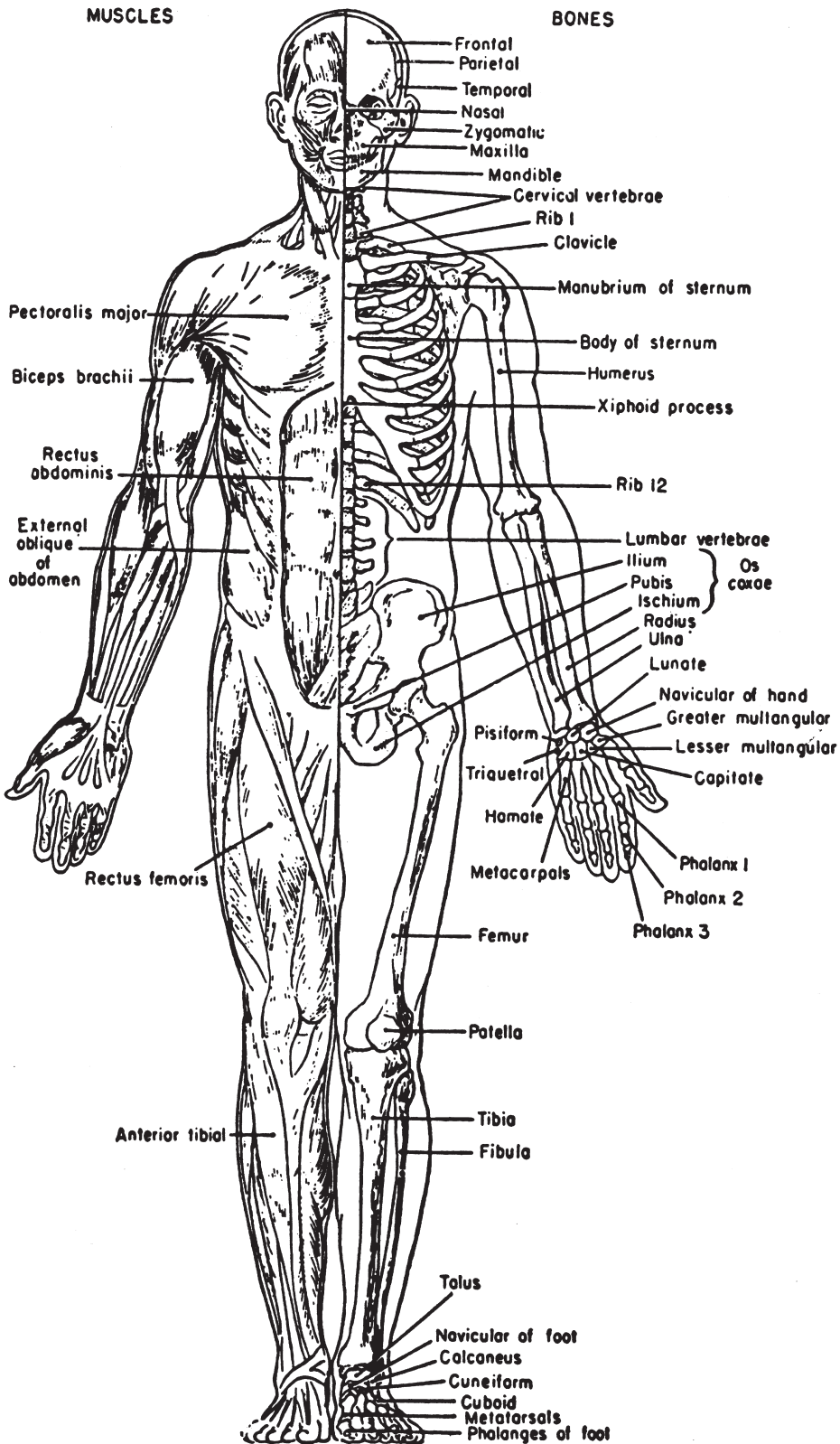
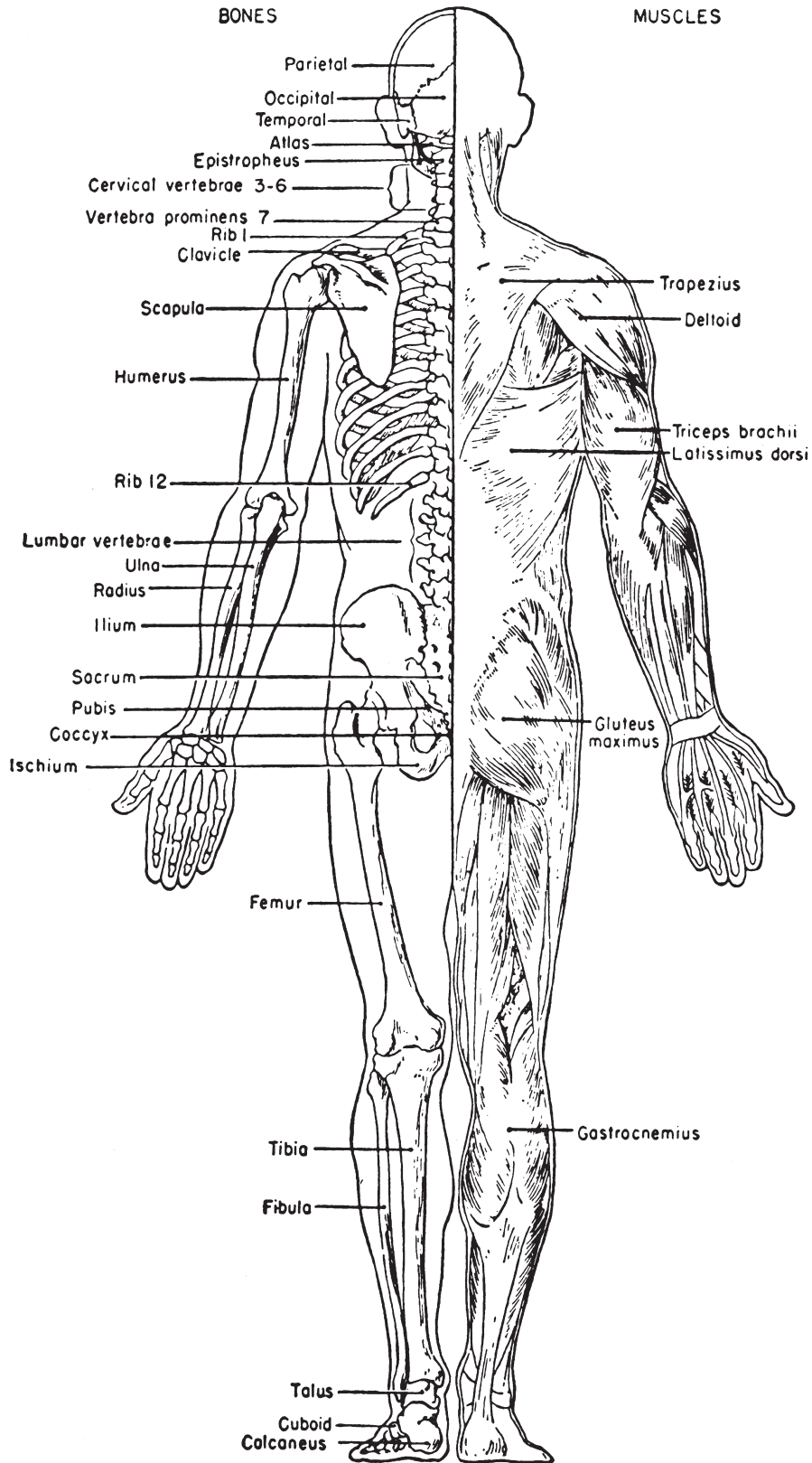


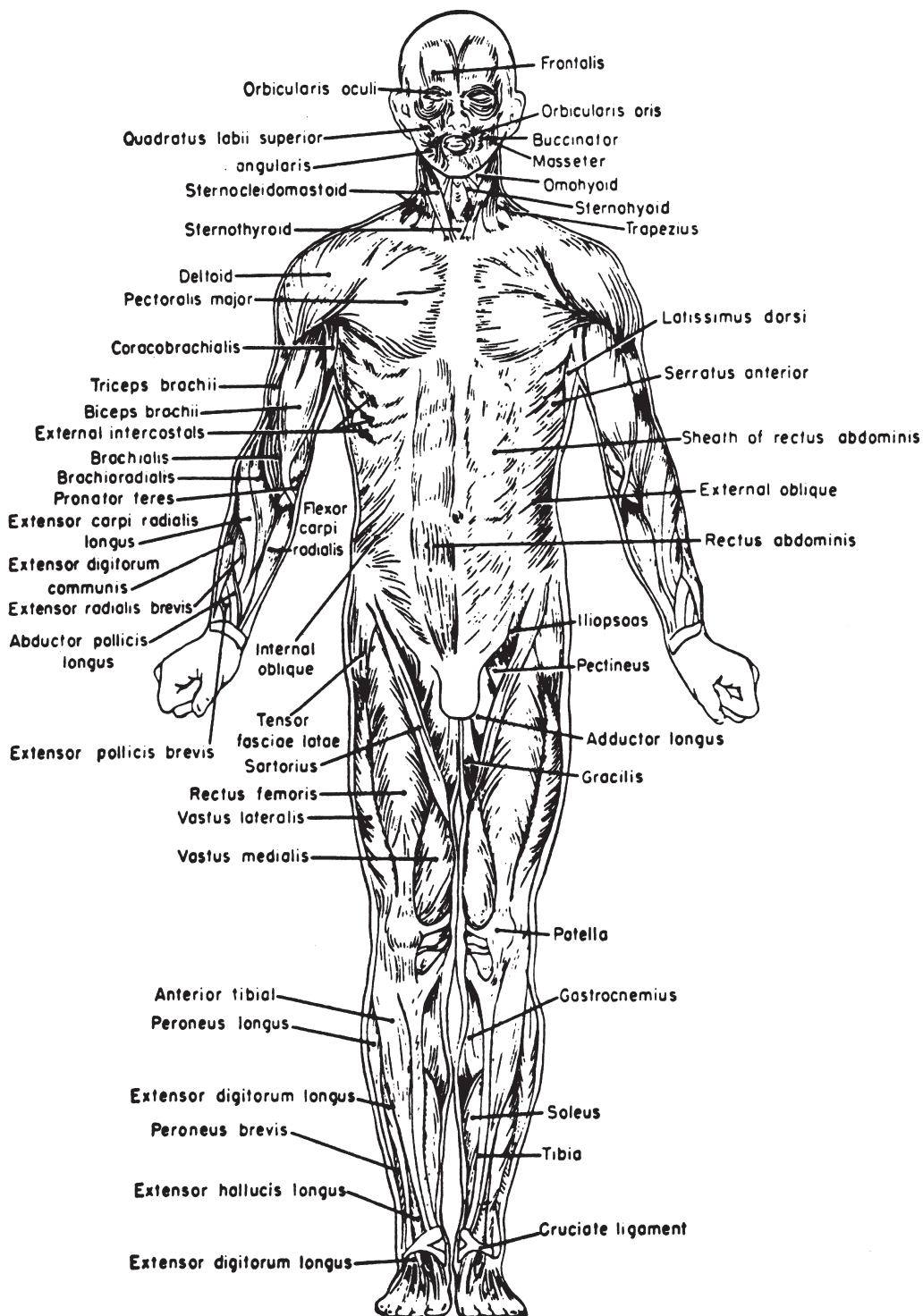
LAWYERS MEDICAL CHARTS



LAWYERS MEDICAL CHARTS



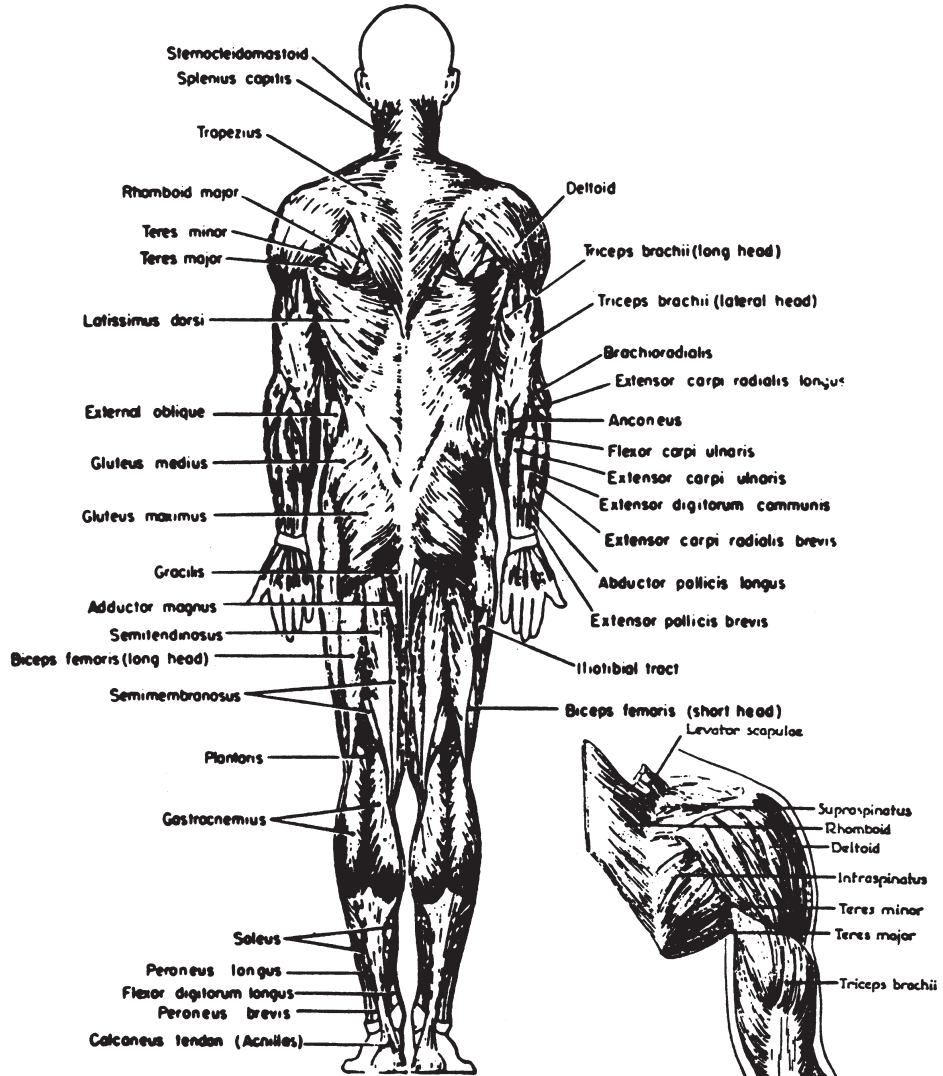
LAWYERS MEDICAL CHARTS



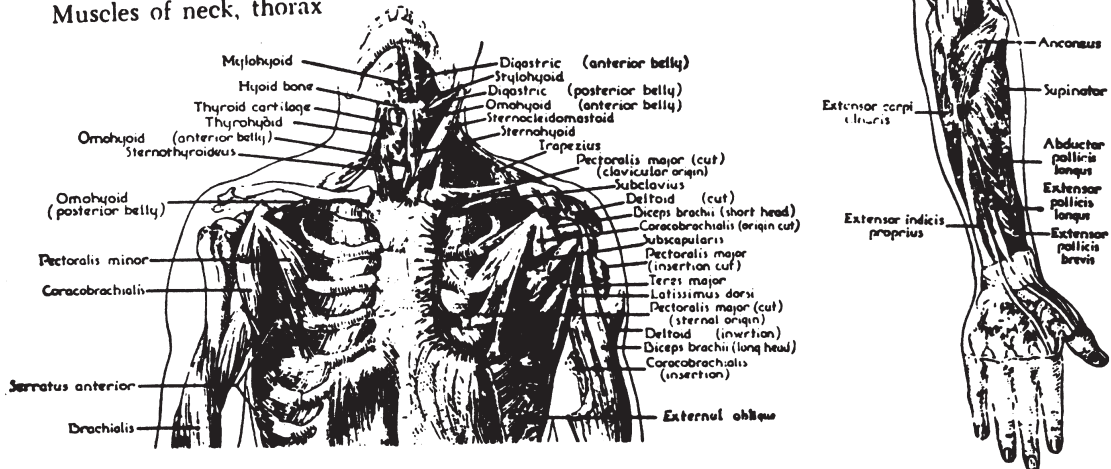
Muscles of the body, anterior view. The deeper muscles are shown on the left side of the face and on the right side of the abdomen.

LAWYERS MEDICAL CHARTS

Muscles of the body, posterior view.

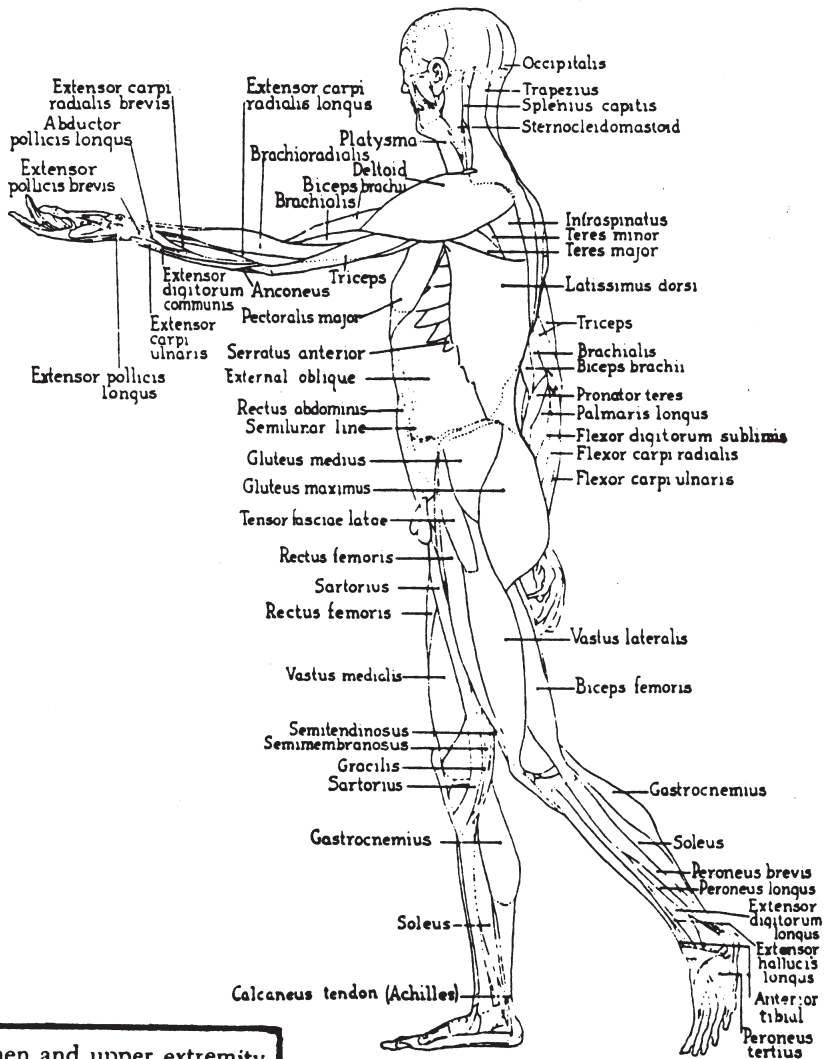


Muscles of neck, thorax

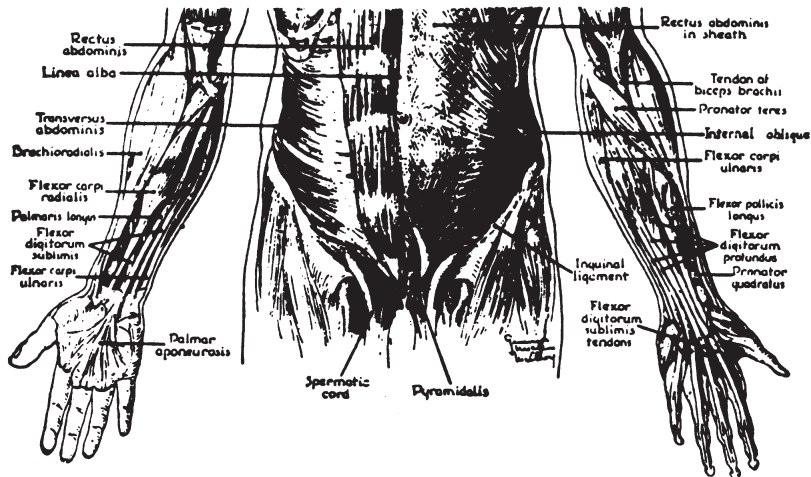


LAWYERS MEDICAL CHARTS

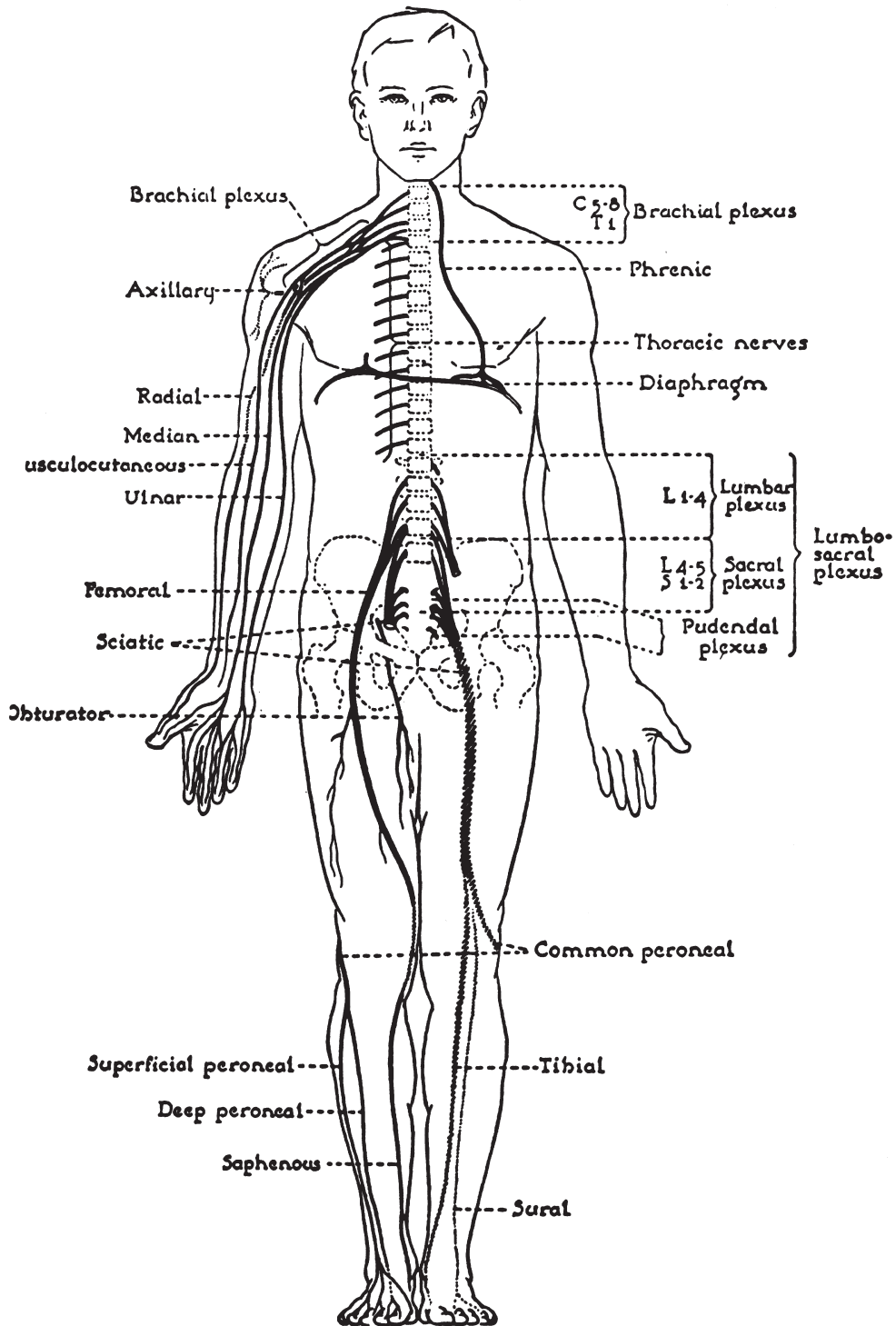
Muscles of the body as seen from the left side.



abdomen and upper extremity

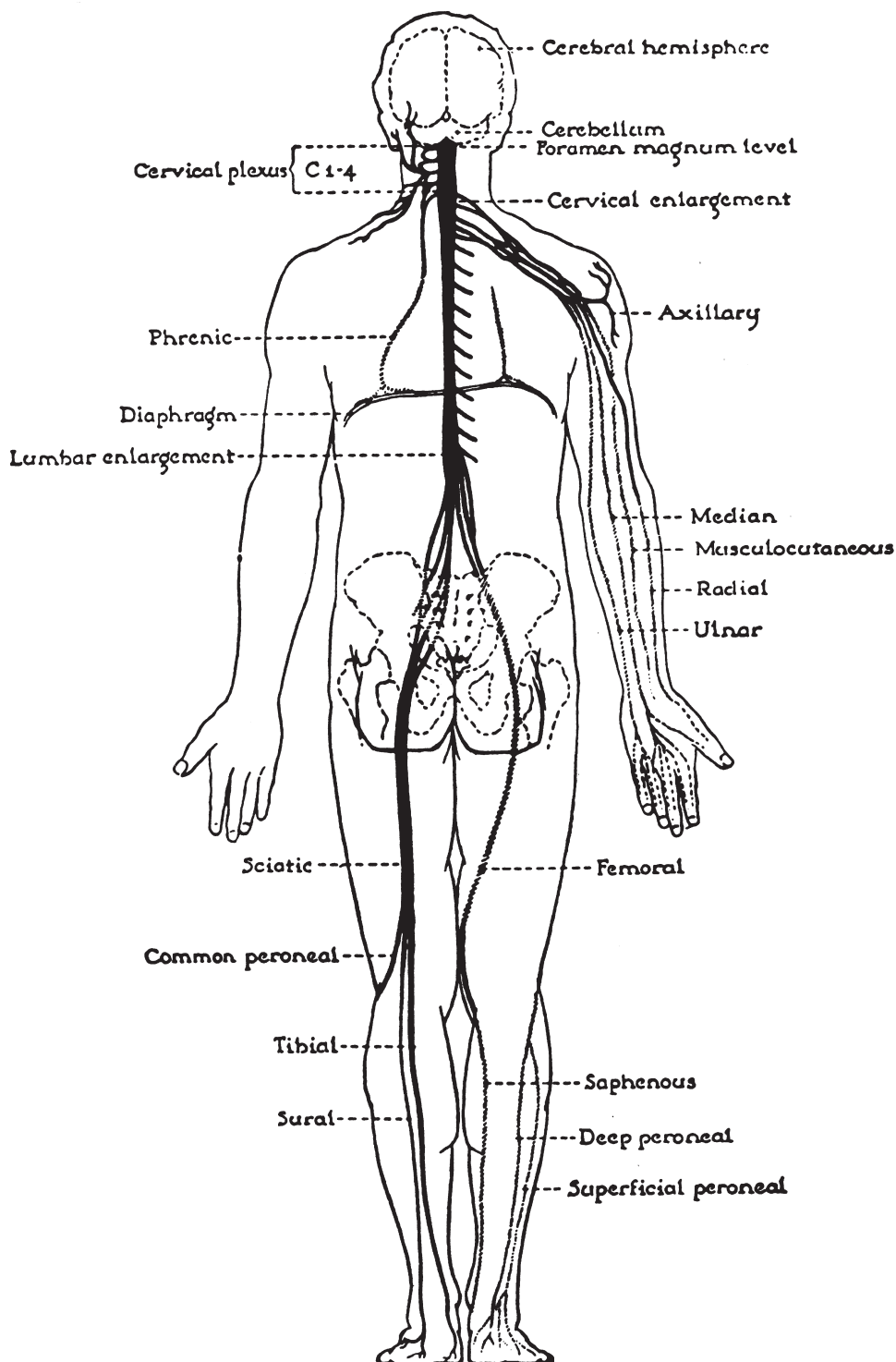


LAWYERS MEDICAL CHARTS



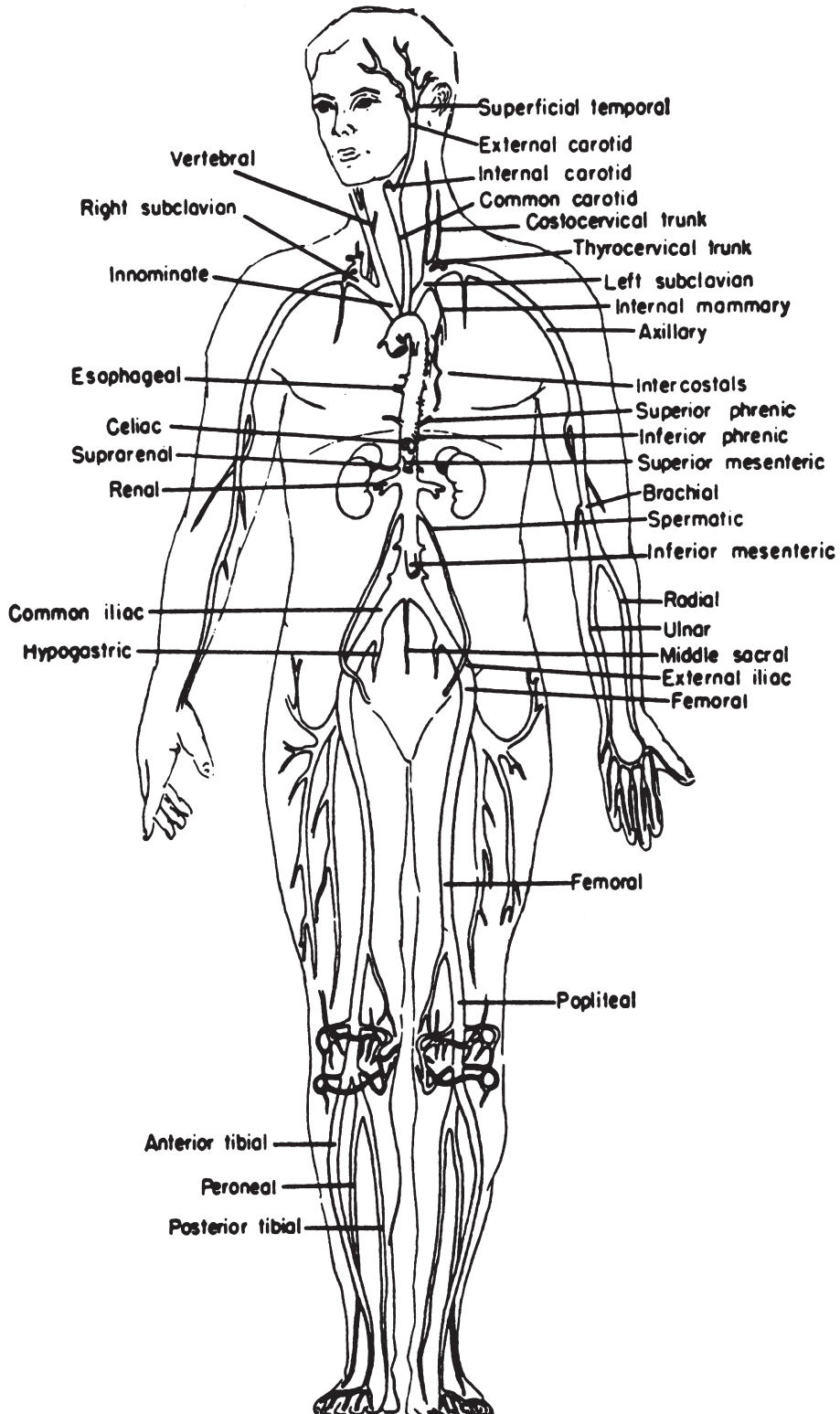
Diagrammatic distribution of certain peripheral nerves projected on the ventral surface. The components of the brachial and the lumbosacral plexuses are shown.

LAWYERS MEDICAL CHARTS



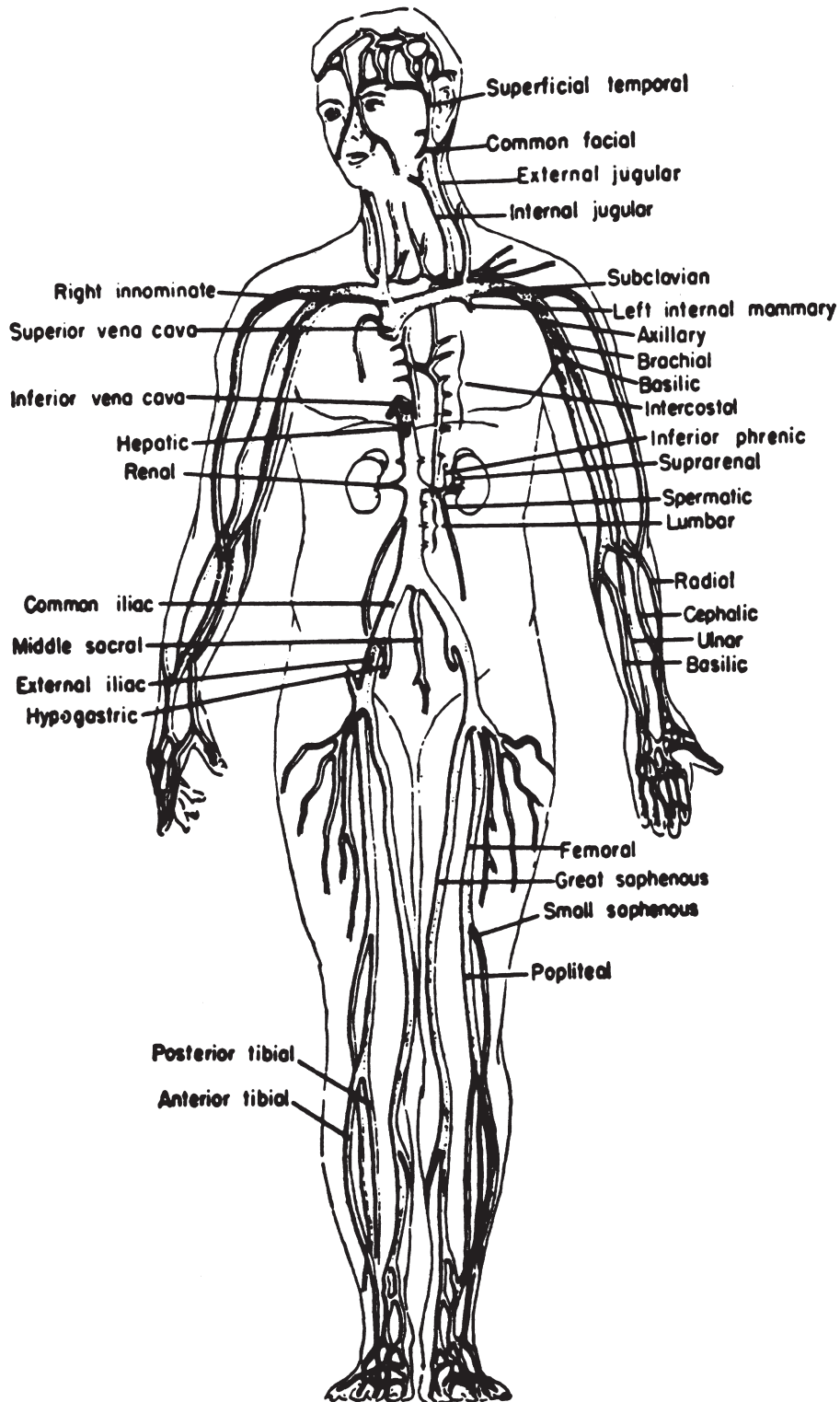
Distribution of peripheral nerves seen from dorsal view. Brain, spinal cord, cervical plexus and phrenic nerve are shown also.

LAWYERS MEDICAL CHARTS



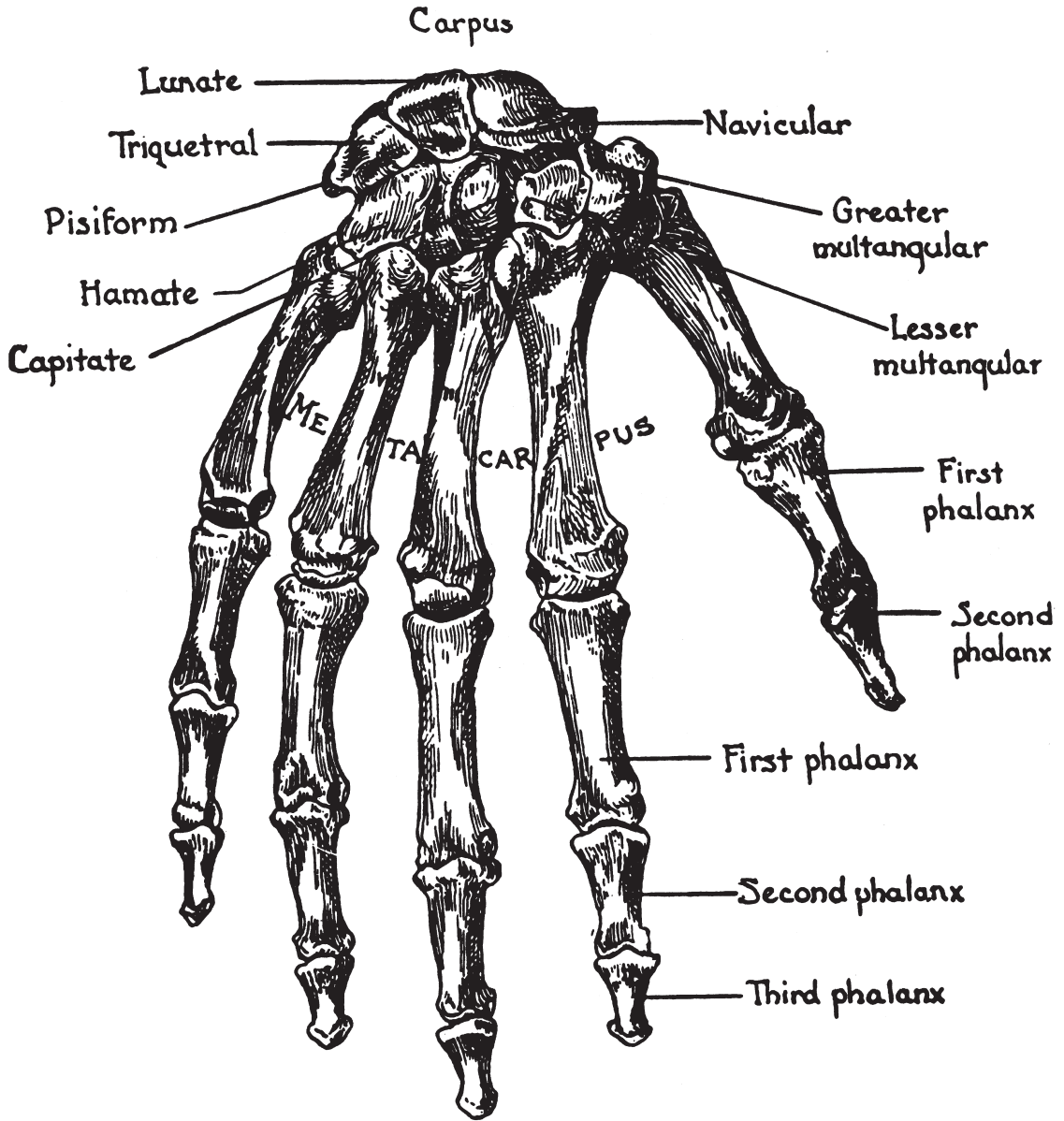
Schematic drawing of the arterial system.

LAWYERS MEDICAL CHARTS



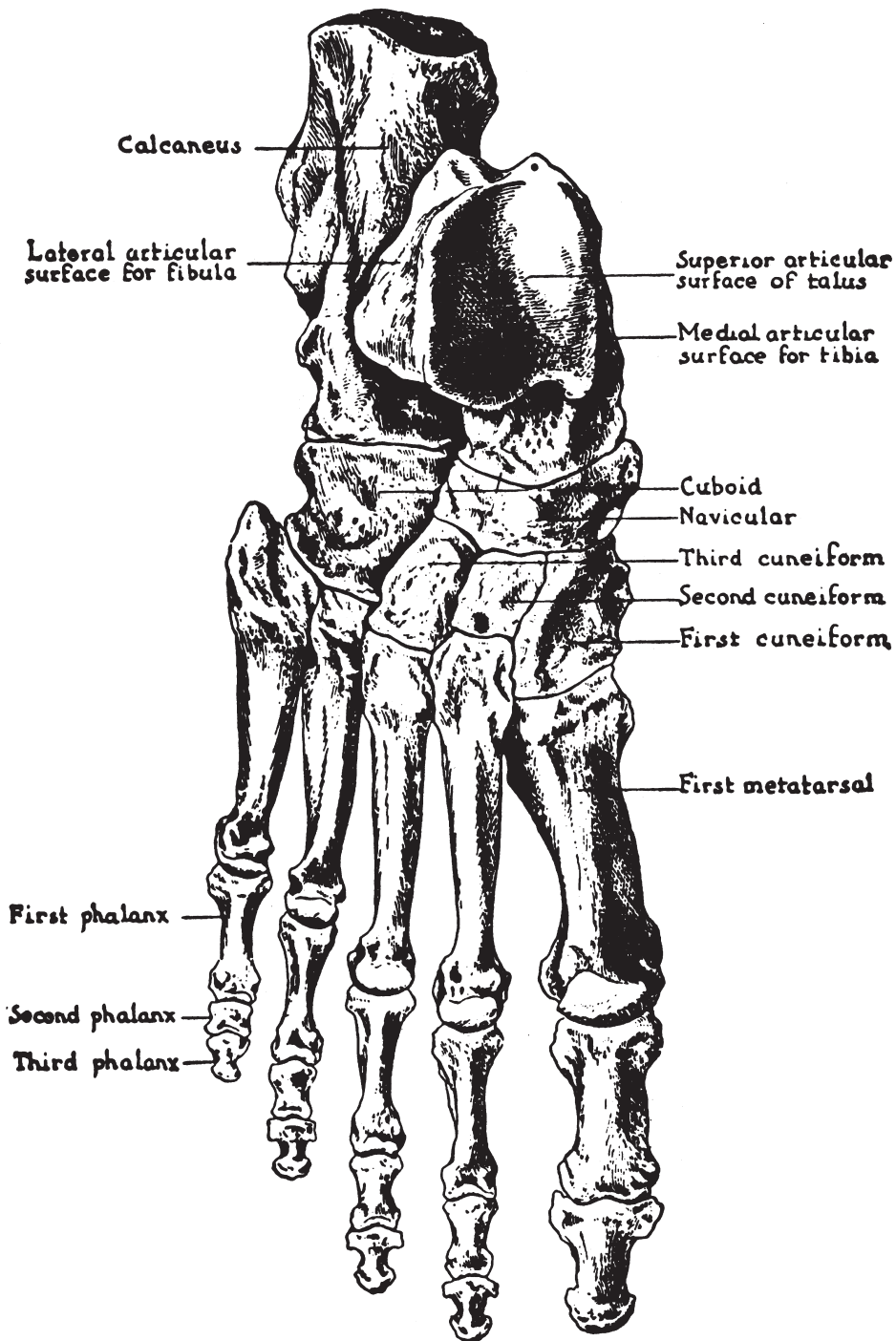
Schematic drawing of the venous system.

LAWYERS MEDICAL CHARTS



BONES OF THE HAND

LAWYERS MEDICAL CHARTS



BONES OF THE FOOT